

Arthritis Following Recombinant Outer Surface Protein A Vaccination for Lyme Disease

CARLOS D. ROSÉ, PAUL T. FAWCETT, KATHLEEN M. GIBNEY

ABSTRACT. As more individuals receive outer surface protein A (OspA) vaccination, adverse effects not detected during phase III clinical trials may become apparent. Although arthritis has been described following other human vaccines, we found no reports of human cases after Lyme disease vaccination. We describe 4 males (2 children, 2 adults) who developed arthritis following recombinant OspA vaccination. The potential arthritogenic effect of OspA suggested by *in vitro* and animal studies finds a clinical correlate in these 4 cases. (J Rheumatol 2001;28:2555-7)

Key Indexing Terms:
LYME VACCINE

ARTHRITIS

Arthritis has been observed after use of a number of human vaccines^{1,2}. Inoculation with recombinant outer surface protein A (OspA) for immunization against Lyme disease has not, to our knowledge, been associated with arthritis during either the clinical trials³ or the postmarketing phase. We describe 4 individuals who experienced articular symptoms after OspA vaccination.

Concerns about potential arthritogenic effects of OspA were raised after the establishment of homology between OspA, a plasmid coded protein on the surface of *Borrelia burgdorferi*, and the human lymphocyte adhesion molecule LFA-1⁴. As a result of molecular mimicry, an autoimmune arthritis with persistent lymphocyte activation in the synovium of a predisposed individual could ensue⁵. Further, a recently published animal study reveals that arthritis can occur when hamsters receive repeat immunization with OspA⁶.

The cases were gathered from 2 different sources. Cases 1 and 2 were seen in consultation at our pediatric rheumatology service and both were participants in the Pediatric Safety Trials of OspA vaccination, a clinical trial sponsored by the vaccine manufacturer. Cases 3 and 4 were part of our own vaccine trial. Briefly, this prospective study involved 20 adult hospital employees who consented to participate in a longitudinal investigation of the evolution of the immune

response to OspA vaccination. All received the approved LYMERix 30 µg (SmithKline Beecham Biologicals, Rixensart, Belgium) according to manufacturer's specifications. The results of this volunteer study have been reported⁷.

Inoculations. Patients 1 and 2 received recombinant OspA as part of the active arm of the Phase III sponsored study. Patients 3 and 4 were hospital employees who chose to receive the vaccine as protection against Lyme disease. Our Institutional Review Board approved both studies.

Serologic testing. IgG antibodies to *B. burgdorferi* were assessed by *Escherichia coli*-adsorbed ELISA and IgG and IgM antibodies were measured by Western blot^{7,8}. Briefly, *B. burgdorferi* strain B31 (American Type Culture Collection) were grown at 29°C in BSK medium. Sera for ELISA testing were diluted 1:80 in *E. coli* solution and added to microtiter wells containing a 10,000 × g supernatant fraction of sonicated *B. burgdorferi*. After incubations and substrate addition the optical density was determined for each microtiter well and converted to an equivalent titer value, with a titer ≥ 1:80 considered positive. Western blots were prepared by transferring *B. burgdorferi* separated in 11% sodium dodecyl sulfate-polyacrylamide gels to nitrocellulose membranes using a semidry blot system. The membranes were cut into strips after blocking with bovine serum albumin, then reacted with sera and developed using a biotin-streptavidin system. For interpretation of Western blots, 2 sets of criteria were applied: (1) in-house criteria, (2) the Dearborn criteria⁷.

CASE REPORTS

Case 1. This 9-year-old boy had the 3rd dose of OspA July 13, 1999. At the end of August, he developed bilateral knee pain with right knee swelling. The symptoms resolved in 4 days. On September 27, he developed a 3 day period of right elbow swelling. In early November, he had left hip arthritis. On November 24, right ankle arthritis was noted, and on the 29th, right thumb swelling was detected. His medical, family, and social histories were

From the Divisions of Immunology and Rheumatology, Department of Pediatrics, duPont Hospital for Children, Wilmington, Delaware, and Thomas Jefferson University, Philadelphia, Pennsylvania, USA.

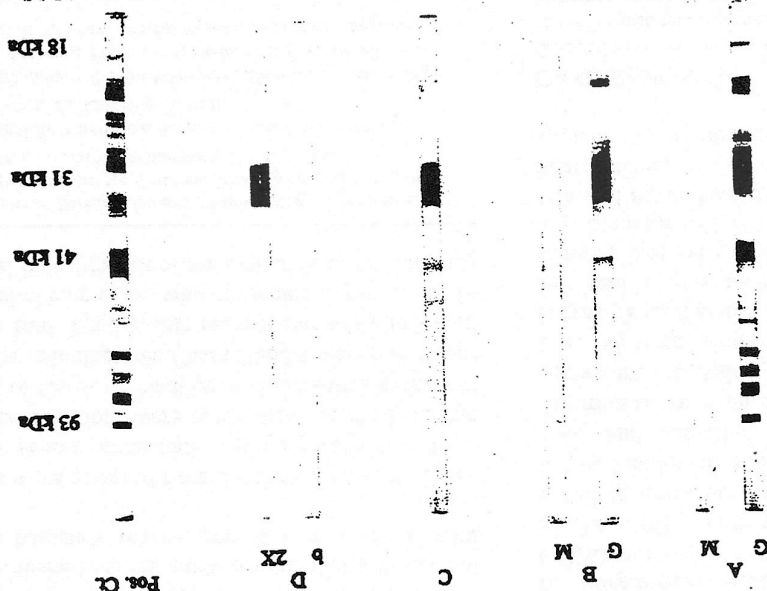
Funded by Clinical Research from Nemours Research Programs, Nemours Foundation, Jacksonville, Florida.

P.T. Fawcett, PhD, Senior Research Scientist, Division of Immunology; C.D. Rosé, MD, Associate Professor of Pediatrics, Division of Rheumatology; K.M. Gibney, Clinical Research Associate, Division of Immunology.

Address reprint requests to Dr. C.D. Rosé, duPont Hospital for Children, 1600 Rockland Road, Wilmington, DE 19899, USA.

Submitted February 8, 2001; revision accepted May 31, 2001.

Figure 1. Western blot strips of Patients 1-4 (blots A-D). Western blot strips labeled A (IgG and IgM) were obtained testing sera from Case 1 and strips labeled B (IgG and IgM) were from Case 2. The strip labeled C shows IgG results from Case 3 (30 days after 2nd dose) and those labeled D were from IgG antibody testing of Case 4 sera at baseline and 30 days after 2nd dose of LYMErix.



unremarkable and there were no additional recent immunizations. On December 2, we confirmed synovitis in the following areas: right elbow, right metacarpophalangeal (MCP), 1st right proximal interphalangeal (PIP), left hip, bilateral knees, and bilateral ankles. His initial laboratory assessment revealed normal peripheral blood count and chemistry, erythrocyte sedimentation rate (ESR) 45 mm/h, and negative antinuclear and antibodies (ANA), antineutrophil cytoplasmic antibodies and rheumatoid factor (RF). HLA-B27 was not detected but HLA-D-DR4 was present. His ELISA test for Lyme antibodies was 1:1280 ($N < 1:80$). IgG Western blot showed the following reactive bands: 93, 69, 66, 64, 54, 53, 41, 39, 31, 30, 28, 26, 25, 22, and 21 kDa (Figure 1, A). We prescribed amoxycillin 60 mg/kg/day for 28 days. On January 14, 2000, there was minimal thumb swelling. At followup 2 months later, he was asymptomatic and without findings.

Judging by the extended immune response observed in the Western blot we believe this child was probably in an asymptomatic phase of natural infection with *B. burgdorferi*. We suspect that the inoculation with OspA could have contributed to production of a polyarticular form of arthritis rarely seen in Lyme borreliosis? The most provocative finding is the development of synovitis one month after vaccine challenge in an infected and until that point, asymptomatic HLA-DR4 + individual.

Case 2. This 16-year-old boy had received the 3rd dose of OspA vaccine in July: in October he described bilateral knee pain and morning stiffness. No other plausible precipitating events were elicited. There was history of migraine and obsessive compulsive disorder. In 1996 he presented with headaches and was diagnosed and treated by other physicians for Lyme disease despite his negative serology (ELISA and Western blot) at that time. There was no history of rheumatic disorders or pertinent family or social history and serology for ANA and RF were negative. In October we noted moderate right knee effusion. Because serologic results were then inconclusive, we treated him with one month of oral doxycycline 100 mg twice daily for 28 days (November–December). In March he had no physical findings and the symptoms were almost resolved. Hemoglobin was 15.4 g%, white blood cell count 7000/mm³, platelets 186,000/mm³, and ESR 5 mm/h. His Lyme antibody titer by ELISA at presentation was 1:640. He had

Case 4. This 43-year-old respiratory therapist received his 2nd dose of OspA vaccine in October 1999. One day later, he started with diffuse pain and malaise. Twenty-four hours later, he developed severe multiple PIP synovitis. He was unable to work for 3 days. On day 5 after receiving PIP synovitis of both hands and 2nd and 3rd MCP. Over 5 vaccines, his symptoms improved. He had a persistently migrating left ring finger for 7 weeks, followed by resolution. His Lyme antibodies by ELISA at baseline and after 1st dose were $> 1:80$, and after the 2nd dose it was 1:640. Western blot results are shown in Figure 1D. Cases 3 and 4 represent transient symmetrical polyarthritides of small joints of the hands following the 2nd dose of OspA. We consider these 2 cases an adverse effect of the vaccine. The clinical presentations of the 2 were very similar, and highly suggestive of a cause-effect relationship.

Case 3. This 53-year-old male orthopedic surgeon volunteered to participate as a subject in our prospective study on the evolution of immune reactivity to OSpA vaccination. He received his first dose uneventfully. Twenty-four hours after his second inoculation, he developed severe flu-like symptoms and arthralgia. Over the course of the day, he noted swelling of his finger joints and toe joints. On examination, he had swelling and redness of all his PIP joints and flexion contracture of the finger joints. He had severe pain on range of motion of the finger joints. The symptoms subsided over 5 days. After the 1st dose his ELISA was positive at 1:80, and after the 2nd dose it was 1:640. Western blot results after the 2nd dose are shown in

2 bands on IgM (41 and 93) and 4 on IgG (66, 41, 31, 21) on the same sample (Figure 1, B). Because serologically there was no evidence of coexisting infection with *B. burgdorferi*, a possible explanation for his syphilis was transient arthritis secondary to OspA vaccination. Figure 1B shows this patient's Western blot strips. There is intense reactivity at the 31 kDa region attributable to vaccination, but also notable is the presence of additional bands. This phenomenon, reported by us⁷ and others^{10,11}, has not been explained completely, as illustrated in this case, it creates problems with Western blot interpretation, perhaps leading to unnecessary treatment.

Both occurred after sensitization and in coincidence with the acquisition of peak antibody level.

DISCUSSION

It is not surprising that vaccines containing a protein(s) encoded by an organism capable of inducing arthritis during natural infection could induce or modify rheumatic symptoms. That phenomenon has been well documented for 2 other arthritogenic infections, hepatitis B and rubella.

These 4 cases represent a spectrum of possible challenges for the clinician practicing in areas endemic for Lyme disease as more individuals receive recombinant OspA. First, OspA vaccine is capable of inducing transient arthritis in humans after the 2nd dose (Cases 3 and 4). It appears to be benign in the long term, polyarticular, symmetrical, and acutely disabling. The prolonged flexor tenosynovitis in our 4th case manifested as trigger finger, however, suggests that symptoms could persist as well. In an infected individual (Case 1), the challenge with OspA may have modulated the clinical pattern of presentation. In this case, a severe and persistent polyarticular arthritis was observed. His symptoms could be attributed solely to infection; however, the temporal association with inoculation and perhaps more important the atypical presentation (polyarticular disease) suggest that OspA played at least a triggering/modulating role. Finally, case 2 represents persistent pauciarticular arthritis following vaccination, likely a vaccine reaction. Because his Western blot showed reactivity to bands other than 31 kDa, a decision to treat was made despite our persuasion that he was not infected, based on our previous investigations on vaccine induced Western blot reactivity. Although transient pauciarticular arthritis could be caused by a number of other diseases (almost always inflammation among children), the lack of alternative triggers, the temporal association between vaccination and disease onset, and the resolution of symptoms over time suggest vaccine induction.

Roughly 10% of patients with Lyme arthritis experience persistent disease beyond one year despite antibiotic therapy¹². Very few, however, will still harbor DNA from the spirochete in their synovial fluid 3 months after treatment¹³, a finding that suggests a noninfectious mechanism for most of them. Instead, host and bacterial factors have been postulated as the causes of disease persistence. HLA-DRB1*0401 was found to be significantly more frequent among those patients with persistent disease. Also, the same investigators found an unusually high frequency of antibodies to OspA (31 kDa) and OspB in the Western blot of patients with prolonged arthritic disease¹⁴. This led to further efforts to characterize the immune response to OspA among such individuals. In a T cell proliferation study it was found that "peptide 15" (aa154-173) of recombinant OspA elicited a vigorous T cell response (secretion of γ -interferon) in patients with prolonged arthritis, particularly those who carried HLA-DRB1*0401⁵. These findings raised concerns

about the arthritogenic potential of OspA. Further, partial homology with the adhesion molecule hLFA-1 and "peptide 8" of OspA added interest to the molecular mimicry model to explain persistent arthritis. hLFA-1 had a favorable predicted binding at the antigen binding groove of the DRB1*0401 moiety, and it is capable of eliciting *in vitro* T cell response among patients with prolonged Lyme arthritis.

Our findings provide clinical support for postinfectious and mimicry models by revealing the capacity of OspA to induce acute arthritis, the possibility of it being associated with a more protracted form of arthritis, and perhaps a modulating effect in individuals who have concurrent Lyme infection. In all cases the disease was self-limiting and to our knowledge inconsequential in the long term.

REFERENCES

1. Pope JE, Stevens A, Houston W, Bell DA. The development of rheumatoid arthritis after recombinant Hepatitis B vaccination. *J Rheumatol* 1998;25:1687-93.
2. Tingle AJ, Allen M, Petty RE, Kenyis GD, Chandler JK. Rubella-associated arthritis. A comparative study of the joint manifestations associated with natural rubella infection and RA 27/3 Rubella immunization. *Ann Rheum Dis* 1986;45:115-9.
3. Steere AC, Sikand VK, Meurice F, et al. Vaccination against Lyme disease with recombinant *Borrelia burgdorferi* outer-surface lipoprotein A with adjuvant. *N Engl J Med* 1988;339:209-15.
4. Gross DM, Forsthuber T, Tary-Lehmann M, et al. Identification of LFA-1 as a candidate autoantigen in treatment-resistant Lyme arthritis. *Science* 1998;281:703-6.
5. Chen J, Field JE, Glickstein L, Molloy P, Huber BT, Steere AC. Association of antibiotic-treatment resistant Lyme arthritis with T cell responses to dominant epitopes of outer surface protein A of *Borrelia burgdorferi*. *Arthritis Rheum* 1998;41:1813-22.
6. Croke CL, Munson EL, Lovrich SD, et al. Occurrence of severe destructive arthritis in hamsters vaccinated with outer surface protein A and challenged with *Borrelia burgdorferi*. *Infect Immun* 2000;68:658-63.
7. Fawcett PT, Rose CD, Budd S, Gibney KM. Effect of immunization with recombinant OspA on serologic tests for Lyme borreliosis. *Clin Diagn Lab Immunol* 2001;8:79-84.
8. Fawcett PT, Rose CD, Gibney KM. Comparative evaluation of absorption with *E. coli* on ELISA tests for Lyme borreliosis. *J Rheumatol* 1995;22:684-8.
9. Rose CD, Fawcett PT, Eppes SC, Klein JD, Doughty RA. Pediatric Lyme arthritis, clinical spectrum and outcome. *J Pediatr Orthop* 1994;14:238-41.
10. Aguero-Rosenfeld ME, Roberge J, Carbonaro CA, Nowakowski J, Nadelman RB, Wormser GP. Effect of OspA vaccination on Lyme disease serologic testing. *J Clin Microbiol* 1999;37:3718-21.
11. Molloy PJ, Berardi VP, Persing DH, Sigal LH. Detection of multiple reactive protein species by immunoblotting after outer recombinant surface protein A Lyme disease vaccination. *Clin Infect Dis* 2000;31:42-7.
12. Johnston EA, Duray PH, Steere AC, et al. Treatment of Lyme arthritis. *Arthritis Rheum* 1994;37:878-88.
13. Nocton JJ, Dressler E, Frudle BJ, et al. Detection of *Borrelia burgdorferi* DNA by polymerase chain reaction in synovial fluid in Lyme arthritis. *N Engl J Med* 1994;330:229-34.
14. Bergstrom S, Bundoc VG, Barbour AG. Molecular analysis of linear plasmid encoded major surface proteins OspA and OspB of the Lyme disease spirochete *Borrelia burgdorferi*. *Mol Microbiol* 1989;3:479-86.