

**Gestational Lyme Borreliosis  
Implications for the Fetus**

Alan B. MacDonald, MD

---

Reprinted from

Rheumatic Disease Clinics of North America

Vol. 15, No. 4, November 1989

**RHEUMATIC  
DISEASE  
CLINICS  
OF  
NORTH  
AMERICA**

VOLUME 15/NUMBER 4  
NOVEMBER 1989

**LYME DISEASE**

Russell C. Johnson, PhD, *Guest Editor*

**W. B. SAUNDERS COMPANY**  
Harcourt Brace Jovanovich, Inc.

Philadelphia London Toronto  
Montreal Sydney Tokyo

## Gestational Lyme Borreliosis

### Implications for the Fetus

Alan B. MacDonald, MD\*

Fetal death, malformation, or retarded development are the most feared potential consequences of intrauterine infection. Some cases of active Lyme borreliosis (LB) in pregnancy have been circumstantially linked to adverse pregnancy outcomes.<sup>3-5,7,9</sup> The majority of women, however, appear to have normal infants in spite of the documentation of Lyme borreliosis during their pregnancies. Epidemiologic studies have attempted to estimate the risk that LB may pose to the fetus. This article will review the epidemiologic evidence and will add the perspectives of the serologist and pathologist. LB in pregnancy is twice the diagnostic problem for the physician, because two patients are simultaneously at risk for tissue injury. The complex spectrum of clinical manifestations of LB in the mother is complementary to an equally complex array of signs and symptoms of prenatal LB in the fetus and infant.

### EPIDEMIOLOGY STUDIES

A 9-year retrospective study of 19 cases of clinically active Lyme disease in pregnant women was completed in 1986 in a joint venture between The Centers for Disease Control and the Yale University School of Medicine.<sup>8</sup> "Only cases in which the outcome of pregnancy was not known were enrolled in the study." In the same time period (1975 to 1985), more than 700 patients with Lyme disease were evaluated at the Yale University School of Medicine. It is uncertain why the patients who were entered into the prospective study did not include all women who developed Lyme disease while they were pregnant, irrespective of the outcome of their pregnancy. Erythema migrans, the pathognomonic cutaneous lesion of LB was identified in 17 women. Two women without EM were included in the study. These patients presented with facial palsy and arthritis (without serologic evidence) and with arthritis and reactive serology.

\* Attending Pathologist, Southampton Hospital, Southampton, New York

One fetal death at 20 weeks gestation occurred in a woman with erythema migrans in the sixth week of her pregnancy followed by meningitis in the seventh week, and arthritis in the sixteenth week. An autopsy of the fetus disclosed no congenital malformations, no inflammatory infiltrates in fetal tissues, and no evidence of spirochetes by culture or histologic methods. A second infant developed cortical blindness at 8 months of age. His mother had erythema migrans in week 27 of pregnancy and was treated with oral penicillin for 10 days. The infant is now 3 years old and has persistent learning disability due to cortical blindness. Three additional adverse outcomes in this cohort included one case each of prematurity with hyperbilirubinemia without kernicterus, syndactyly of the second and third toes, and self-limited hyperbilirubinemia with a concurrent generalized petechial and vesicular rash in a full-term infant.

The epidemiologist's summation observations included the following: (1) one second-trimester abortion was not expected to occur by chance in a group of 19 pregnancies and therefore was an important finding; (2) a case of cortical blindness and developmental delay could not be linked to maternal infection; (3) no two adverse outcomes were similar and therefore a link between Lyme disease and adverse fetal outcome could not be proven; and (4) the frequency of adverse outcomes prompted a consensus recommendation that immediate penicillin therapy be instituted for pregnant women who develop Lyme disease.

### SEROLOGY STUDIES

The CDC-Yale Study of Lyme disease in pregnancy did not have serology data for each of the patients. Patients were diagnosed with Lyme disease based on the erythema migrans lesion. Seroconversion is expected in only 40 to 60 per cent of patients after the EM lesion is identified. Examination of umbilical cord blood specimens from five clinically normal infants showed no evidence of detectable antibodies to BB. The authors concluded, based on the seronegative status of the five infants, that "there was no evidence of occult infection." (A single negative serologic result from umbilical cord blood certainly does not exclude LB, especially in light of the recent documentation of a seronegative state in certain patients with chronic disease<sup>4</sup> and in light of the observations of Stokes in prenatal syphilis. A sixth infant's umbilical cord blood specimen was positive for antibodies to BB, but 7 months later the infant was seronegative. The authors did not indicate whether this infant's antibodies were of the IgM class (indicating intrauterine infection) and did not state whether they believed that this infant had an occult infection which might have reverted to a seronegative state as a result of antibiotic therapy.)

Williams and colleagues<sup>11</sup> conducted a prospective study of newborn infants to determine whether clinical and serologic differences could be detected between babies whose mothers had resided in an endemic area for LB versus those whose mothers resided in a nonendemic area for LB. In 255 infant cord blood specimens from an endemic



area, 10.2 per cent had some detectable antibody to BB and in 166 from a nonendemic area 2.4 per cent showed detectable antibodies to BB in umbilical cord blood. Major congenital malformations were not significantly different between the two groups, but low birth weight and neonatal jaundice were more often observed in babies in the endemic area. None of the observed parameters were statistically different between infants in the two groups.

A conspicuous absence of fetal deaths or miscarriages in the Williams patient study group is an inevitable consequence of the selection process in this study. Only live born infants were included. The opportunity to observe congenital anomalies associated with miscarriages, stillbirth, or perinatal infant death was not permitted due to the design of the study. Therefore, the author's conclusion that no association can be supported between gestational LB and congenital malformation should be a highly qualified statement with multiple disclaimers.

#### PATHOLOGY STUDIES

Schlesinger et al<sup>7</sup> proved in their 1985 report that BB could be vertically transmitted to the fetus. Spirochetal fragments were identified by silver impregnation techniques in autopsy fetal spleen, kidney, and bone marrow. The immediate cause of neonatal death at 39 hours after delivery was cardiac failure secondary to the hypoplastic left heart complex of anomalies. Although the Schlesinger report stated that BB was not found in the fetal myocardium, MacDonald subsequently succeeded in demonstrating BB in the myocardium from the Schlesinger case using an immunohistochemical technique (Fig. 1). MacDonald<sup>4,5</sup> reported four additional cases of maternal fetal transmission of BB with cardiac anomalies in three of the fetuses. Spirochetes were seen on darkfield examination of fetal livers in all cases and histopathology studies confirmed that spirochetes were present in various fetal and placenta tissues in all cases. Weber and colleagues<sup>9</sup> described transplacental transmission of BB followed by neonatal infant death in a case from Germany. Spirochetes were found in the brain and liver at autopsy despite the fact that the mother had taken penicillin promptly after the erythema migrans lesion appeared in the second trimester of her pregnancy. Lavoie and colleagues<sup>3</sup> reported a full-term neonatal death due to aortic thrombosis in which BB was cultured from the infant's brain. Spirochetes were not identified in fetal tissues by histologic methods. Table 1 abstracts various parameters from these autopsy cases.

#### ANALYSIS—HISTOPATHOLOGY STUDIES OF GESTATIONAL LB

Autopsy evidence for gestational LB establish that spirochetes are in fetal or placental tissue. Such cases show that serological evidence is often lacking when maternal blood is tested for antibodies to BB immediately after the delivery of a living or dead fetus. Routine tissue studies

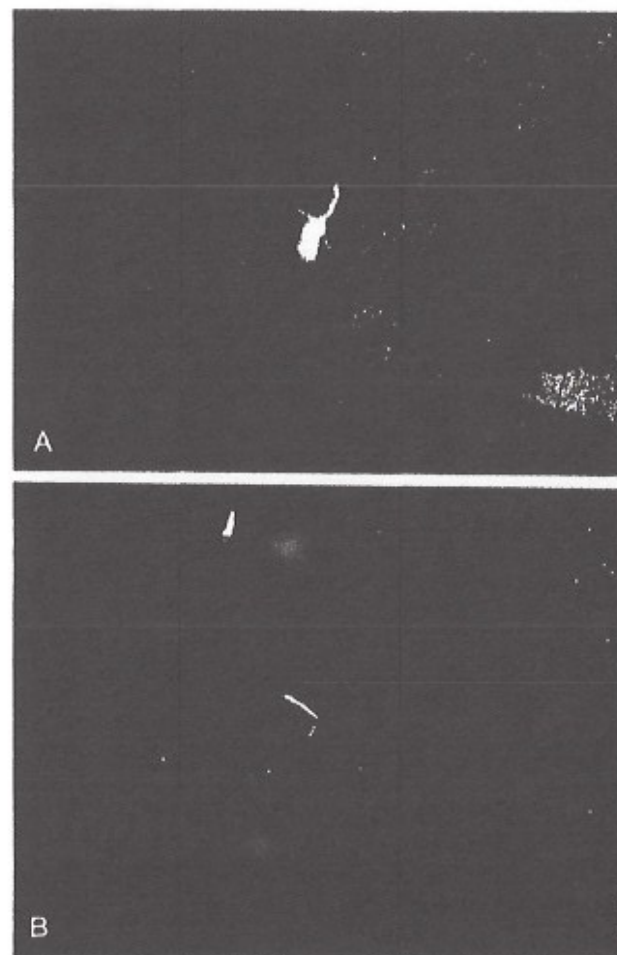


Figure 1. A, *B. burgdorferi* in fetal autopsy myocardium. Indirect immunofluorescence, 1000X magnification. B, *B. burgdorferi*, reference strain B31 in agarose. Indirect immunofluorescence, 1000X magnification.

with ordinary microscopic techniques, namely hematoxylin and eosin stained sections, fail to provide clues that infection has reached the fetus because none of the autopsies to date has shown inflammation in the tissues which contained BB. In each of the previously published cases, a strong index of suspicion was the sole cause for the intricate and exhaustive medical investigation specifically directed toward the subtle clinical

Table 1. Clinical Parameters from Autopsy Cases

CITATION	EM LESION	MATERNAL SEROLOGY	TISSUE INFLAMMATION	TISSUE SPIROCHETE	CARDIAC FETAL ANOMALY
Schlesinger	+	—*	—	+	+HLC†
Case 1	+	+	—	+	+VSD‡
Case 2	—	—	—	+	+ASD§
Case 3	—	—	—	+	+CA¶
Case 4	—	—	—	+	—
Weber	+	—	—	+	—
Lavole	—	—	—	—	—

\* IFA titer of 1/128 is not significant by 1989 CDC criteria for case definition of Lyme borreliosis.

† Initial Lyme serology in 1985 is negative by IFA and ELISA; repeat testing on frozen serum 3 years later were positive.

‡ Hypoplastic left heart complex of malformations.

§ Ventriculoseptal defect of the atrioventricular type.

¶ Atrial septal defect of the ostium primum type.

| Coarctation of the aorta; infantile type.

and histopathologic evidence of LB and its spirochetal agent BB. Patience and diligence are required if the histopathologist is to succeed in visualizing BB with oil immersion magnification. There are many potential pitfalls and there are many opportunities to fail when looking for the spirochete.

### LEVELS OF PROOF OF ACTIVE LYME BORRELIOSIS

Three perspectives—epidemiology, serology, and histopathology—offer nonconvergent views of the potential impact of LB on human pregnancy. Nonconvergence tends to interfere with clear vision and clear thought. The serologist's tools for antibody detection have technical, biologic, and epistemologic shortcomings. False positive and false negative results are menacing problems that perplex the diagnostician.<sup>1</sup> If false results are to be feared, it is the false negative result which holds the greatest peril for the patient. Under the best of circumstances, as noted in the CDC report of Lyme disease in pregnancy, "results of serological tests for Lyme disease are often negative during the first several weeks of infection."<sup>8</sup> From a biologic perspective, most of the fatal cases of LB in pregnancy were reactive either in titers in the borderline region or were completely nonreactive in serologic tests. The tendency toward seronegativity in pregnancy makes maternal serology a less satisfactory discriminator of maternal infection and useless as a practical tool to predict the actual state of the fetus (unless the patient and physician are willing to accept the hazard of direct sampling of fetal blood while the fetus is still in utero). Erythema migrans is a pathognomonic tool which is exploited by the epidemiologists to diagnose active early Lyme borreliosis.

It is estimated that one half of patients with LB never develop the erythema migrans lesion. Furthermore, erythema migrans in the mother does not predict whether the infection will remain localized to the skin or whether the infection may have already entered the bloodstream and pose a threat to the health of the fetus. There is no placental protection or barrier that protects the fetus from the spirochete once the microbe has entered the maternal bloodstream. Therefore, if we seek the truth, we must seek the spirochete directly by pathologic study of available tissues from the products of conception.

### TWO PATIENTS SIMULTANEOUSLY AT RISK: A DOCTOR'S DIAGNOSTIC DILEMMA

LB in the pregnant patient simultaneously involves two patients, the mother and her fetus. The indirect nature of the diagnostic process regarding the presence of disease, its activity, its potential severity, and its response of appropriate antibiotic therapy are uncertain for the mother, and far more difficult for the fetus. Theoretical possibilities are presented in Table 2.

### A CONCEPTUAL MODEL OF PRENATAL SYPHILIS

The clinical diversity of LB is a formidable diagnostic challenge to the physician which is matched by the labyrinthine complexity of prenatal syphilis. Three quintessential paradigms from the literature of congenital syphilis appeared in the textbook by Stokes in 1945:<sup>9</sup>

1. "Prenatal syphilis is a collection of rare events of interest to the connoisseur of the elegant art of medical investigative diagnosis."
2. "The diagnosis of syphilis in a dead fetus is just as difficult as the diagnosis of syphilis in a living fetus."
3. "Never 'always,' Never 'never.'"

Additional wisdom from 400 years of cumulative observation of syphilis with special emphasis on the situation of pregnancy is abstracted in Table

Table 2. Potential Situations of Gestational Lyme Borreliosis

MOTHER	FETUS	CASE NUMBER
Clinical disease	No disease	14
Subclinical disease	Active disease	4-12
Clinical disease	Clinical disease	1
<i>Effects of Antibiotic Therapy: Mother Versus Fetus</i>		
Antibiotic cure	Antibiotic cure	12, 14
Failure	Failure	—*
Cure	Failure	Weber, 13
Failure	Cure	—*

\* No published cases for these categories.



Table 3. Vignettes from Clinical Observation of Prenatal Syphilis

"Seronegative results are absolutely untrustworthy."
"The exact date of maternal or fetal infection is often impossible to determine."
"Asymptomatic seronegative mothers may bear syphilitic children."
"Prenatal syphilis may only appear as a tardive manifestation in the child after birth."
"Repeated unsuccessful pregnancy (miscarriage or stillbirth) has a high value as a diagnostic clue to maternal syphilis."

3. The diversity of prenatal syphilis at the clinical level is illustrated below and the laboratory diversity of prenatal syphilis is presented in Table 4 (note that approximately 20 per cent of infants who acquired syphilis in utero were seronegative at birth).

The manifestations of heredosyphilis in newborn babies include: eruptive cutaneous lesions; snuffles; irritability; fissured lips; pseudo-paralysis of Parrot; anemia; mucous patch; anal condyloma lata; aphonic cry; marasmus; nephritis; icterus neonatorum; and no clinical symptoms detectable at delivery.

Tardive manifestations of prenatal syphilis that are not apparent at birth, but develop in childhood or adolescence include: Hutchinson incisor; scaphoid scapula; interstitial keratitis; eighth nerve deafness; saddle nose; hydroarthrosis of Clutton; optic atrophy; and hydrocephalus.

#### THE SOUTHAMPTON HOSPITAL FETAL BORRELIOSIS STUDY

Southampton Hospital is a 192-bed community hospital serving the eastern end of Suffolk County, a coastal region of Long Island in New York State. Between 650 and 750 babies are delivered each year by the hospital's obstetric staff. Lyme borreliosis is hyperendemic in Suffolk County and the yearly LB infection rates have consistently been among the highest in the United States since 1982 when the New York State Department of Health began its surveillance program. High rates of infection predict that the insect vector, *Ixodes dammini*, is ubiquitous in our communities and that the percentage of ticks carrying the spirochete is high in the communities served by the hospital. Medical entomologists

Table 4. Prenatal Syphilis: Serial Studies of the Mother and Child

TYPE	SEROLOGY OF SYPHILIC MOTHER	INFANT'S SEROLOGY AT BIRTH	ULTIMATE SYPHILIS STATUS OF CHILD	NUMBER OF CASES	PERCENTAGE TOTAL
1	+	+	+	36	12
2	+	-	+	54	18
3	-	-	+	35	4
4	-	+	+	1	0.3
5	+	+	-	25	8
6	+	-	-	101	35.7
7	-	-	-	72	24

have demonstrated that between 60 and 100 per cent of Ixodid ticks carry the infection, depending on the tick habitats sampled and the time of the year that the ticks are collected. (Our medical community includes Shelter Island, New York, which is Dr. William Burgdorfer's source of the Ixodid ticks from which he identified "*Borrelia burgdorferi*" in 1981). The extraordinary interest in Lyme borreliosis in pregnancy at Southampton Hospital is in part due to the opportunity to see various manifestations of the infection which our ecosystem presents and which may not yet exist in other areas.

A 7-year retrospective analysis of perinatal autopsies performed from 1978 to 1985 (Table 5) and a 3-year prospective study of perinatal deaths from 1985 to 1988 has yielded evidence that *Borrelia burgdorferi* is detectable in some perinatal autopsy tissues.

#### Case 1: Fetal Lyme Borreliosis with Ventriculoseptal Defect

A 24-year-old white woman was admitted in February 1985 in labor at term of her pregnancy. Ultrasound examination showed that the fetus was dead when she arrived at the hospital. Following the delivery of her stillborn infant and completion of the fetal autopsy, a retrospective interview established that she had acquired Lyme borreliosis in the first trimester of her pregnancy outside of Salt Lake City, Utah. Postpartum serologic studies yielded conflicting results because the Centers for Disease Control found strongly reactive results by IFA and ELISA, as did the New York State Department of Health; however, the Yale University laboratory of Dr. Allen Steere could detect no evidence of specific antibodies for *B. burgdorferi*. Fetal viscera showed *B. burgdorferi* in the liver, adrenal, brain, heart, and placenta. Spirochetes were seen by dark-field examination of fetal liver and these bound specific monoclonal antibody H5332. No microscopic inflammation was identified in tissue sections which contained the spirochete (Fig. 2). Points to emphasize from this case are: (1) lack of tissue inflammation in infected tissues; (2)

Table 5. Tabulation of Southampton Hospital Perinatal Autopsies 1978-1988

Total autopsies	24
Autopsies showing evidence of Lyme borreliosis	4
Autopsy diagnosis	
Group I (no evidence of gestational LB N = 20)	
Abruptio placenta	4
B 19 Parvo virus	1
Prune belly syndrome	1
Thanatomorphic dwarf	1
Crouzon disease	1
Bilateral renal agenesis	2
Stillborn (cause unknown; no cardiac anomalies seen)	10
Group II (evidence of gestational LB n = 4)	
Ventriculoseptal defect (AV canal type)	1
Ventriculoseptal defect (unspecified type)	3
Neural tube defects (hydrocephalus and meningocele)	1
Absence of left hemidiaphragm	1

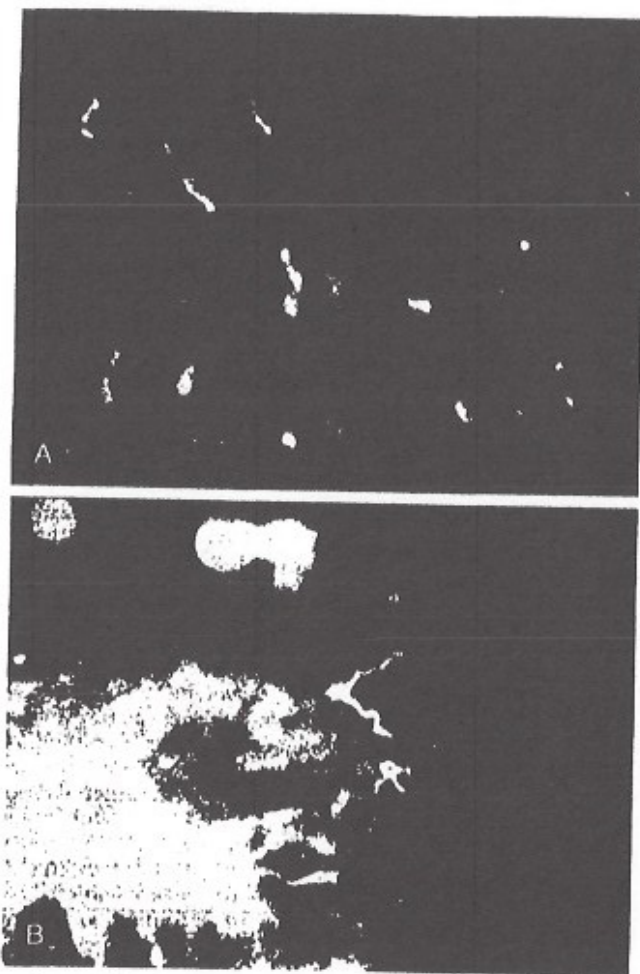


Figure 2. A, *B. burgdorferi* in fetal autopsy myocardium (Case 1). Indirect immunofluorescence, 1000X original magnification. B, *B. burgdorferi* in fetal autopsy adrenal gland (Case 1). Indirect immunofluorescence, 1500X original magnification.

discrepancy in serology testing; (3) positive cultures of spirochetes from fetal liver; (4) concurrence of first trimester infection with events of cardiac organogenesis and subsequent identification of a ventriculoseptal defect; (5) intrauterine fetal growth retardation; and (6) acquisition of infection in a "nonendemic area" and identification of infection by entirely retrospective analysis.

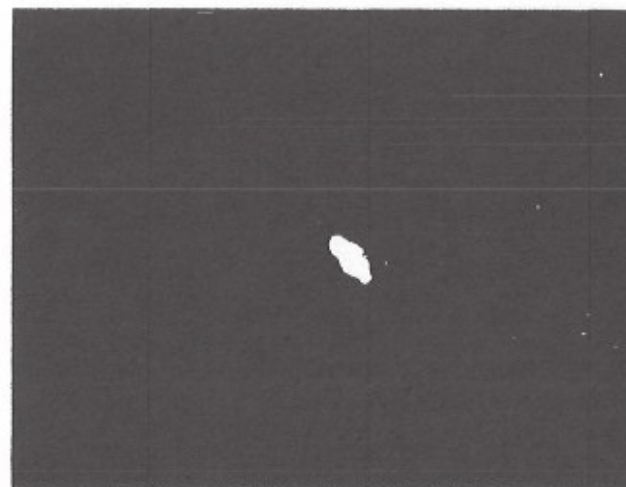


Figure 3. *B. burgdorferi* in fetal placenta. Indirect immunofluorescence, 1000X original magnification.

#### Case 2: Fetal Lyme Borreliosis with Miscarriage at 19 Weeks Gestation

A 22-year-old white woman became pregnant while residing on a farm in Suffolk County, New York. She recalled no tick bite and did not see an erythematous skin lesion. Severe toxemia of pregnancy in week 17 of pregnancy was marked by hypertension, facial edema, and albuminuria and peripheral edema. A macerated 514 gm stillborn female fetus with an atrial septal defect was delivered in week 19. Postpartum maternal blood showed negative results in two laboratories for specific antibodies to *B. burgdorferi*. *B. burgdorferi* was identified in tissue by indirect immunofluorescence (Fig. 3).

#### Case 3: Fetal Lyme Borreliosis with Miscarriage at 23 Weeks Gestation

A 37-year-old white woman became pregnant while residing on Shelter Island, New York. Fetal and maternal health appeared normal through week 20 of gestation. An amniocentesis at week 20 showed a normal fetal karyotype. Toxemia of pregnancy began in week 22 with hypertension and proteinuria. In week 23 a 490 gm stillborn male fetus was delivered. The mother's medical history was remarkable for an undifferentiated collagen vascular disorder which was in sustained clinical remission while she was pregnant, but which reactivated after she lost the fetus. A postpartum Lyme serology test was nonreactive in two laboratories, but an FTA-ABS test for syphilis was reactive at an unstated dilution and was interpreted as a biologic false positive result reflecting her collagen disease. A fetal autopsy showed coarctation of the aorta and no inflammation of fetal viscera in spite of visceral spirochetosis. *B.*



*burgdorferi* was identified in tissue by indirect immunofluorescence (Fig. 4).

#### Case 4: Fetal Lyme Borreliosis with Miscarriage at 15 Weeks Gestation

A 32-year-old Oriental woman became pregnant while residing in East Hampton, New York. Her course was uneventful in the first trimester of her pregnancy. She miscarried at 15 weeks gestation and delivered an 85 gm female fetus with no congenital anomalies. Spirochetes were observed in the fetal liver and in the placenta, but no inflammation was found in fetal viscera. Postpartum maternal serology was negative for specific antibodies to BB. *B. burgdorferi* was identified in tissue by indirect immunofluorescence.

#### Case 5: Fetal Lyme Borreliosis in Term Delivery and Postnatal Death After 4 Hours

A 25-year-old black woman presented in September 1978 in labor in week 39 of pregnancy. Her antepartum course was remarkable only for a brief episode of vaginal bleeding in her second month of pregnancy. A 2250 gm female infant showed multiple anomalies at delivery including hydrocephalus, omphalocele, clubfoot, spina bifida, and meningomyelocele. Respiratory distress developed in the newborn nursery and 4 hours later the infant died. Autopsy disclosed a large ventriculoseptal defect as an additional malformation. Spirochetes were identified by immunohistochemistry in a retrospective examination of fetal autopsy tissue.

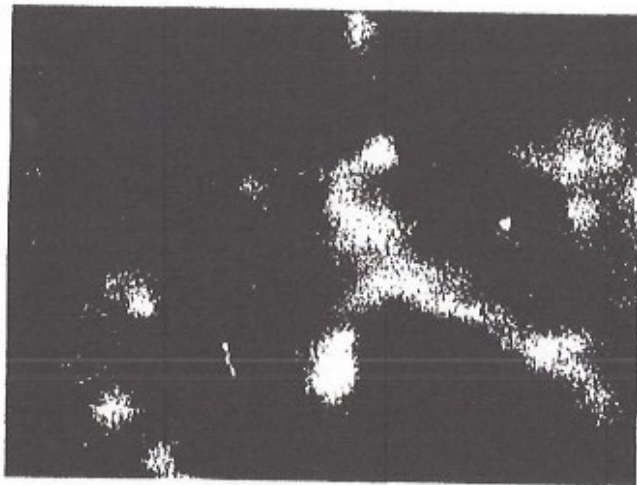


Figure 4. *B. burgdorferi* in fetal kidney. Indirect immunofluorescence, 1500X original magnification.

#### Case 6: Fetal Borreliosis, Term Pregnancy, With Postnatal Death at 30 Minutes

A 33-year-old white woman was admitted in February 1979 in week 40 of pregnancy. Her antepartum course was remarkable for uterine growth retardation as detected in serial obstetrical ultrasound examinations. A 1950-gm female infant showed poor color and poor respiratory activity at birth. The infant showed profound bradycardia with heart rates of less than 60 beats per minute, with progressive decline in cardiac output and death 30 minutes after birth despite maximum support in the neonatal nursery. Autopsy disclosed a large (1 cm diameter) ventriculoseptal defect and showed an absence of the left hemidiaphragm with herniation of abdominal viscera into the left hemithorax. Spirochetal fragments were identified by indirect immunofluorescence in a retrospective examination of fetal autopsy tissue.

#### Case 7: Fetal Lyme Borreliosis with Miscarriage at 17 Weeks Gestation

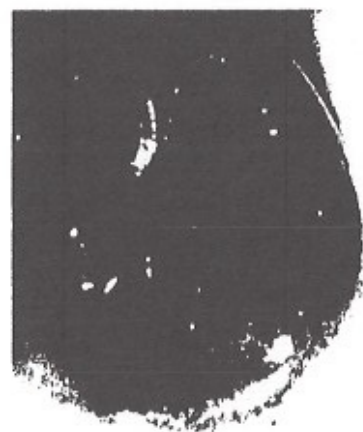A 34-year-old black woman was admitted in March 1986 in week 17 of her third pregnancy. She delivered a 30 gm male fetus in the emergency room. In the 2 weeks prior to admission, she had experienced vaginal bleeding and abdominal cramping. An obstetric ultrasound examination in week 12 of pregnancy had shown a normal appearing fetus with no abnormalities in head circumference or femur length and suggested normal fetal development. An autopsy disclosed fetal hydrocephalus and spirochetes were identified in fetal brain by indirect immunofluorescence (Fig. 5). Postpartum maternal blood showed a nonreactive result in Lyme serology.

#### Case 8: Fetal Lyme Borreliosis with Miscarriage at 16 Weeks Gestation

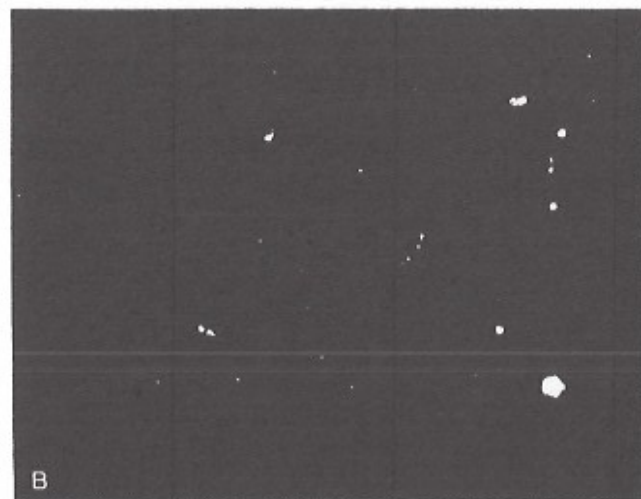
A 21-year-old black woman was admitted in July 1988 in active labor in week 16 of her third pregnancy. In the 2 weeks before admission, she experienced vaginal bleeding, abdominal cramps, low-grade fever, and on the day of admission noted a foul-smelling vaginal discharge. A 150-gm macerated male fetus showed no malformations at autopsy. Spirochetes were identified in fetal brain with immunohistochemistry using monoclonal antibodies (Fig. 6). Postpartum maternal blood was negative for antibodies to *B. burgdorferi*. No inflammation was found in fetal viscera at autopsy.

#### Case 9: Fetal Lyme Borreliosis with Miscarriage at 12 Weeks Gestation

A 25-year-old white woman was admitted in active labor in November 1986 at week 12 of her third pregnancy. She delivered a nonmacerated 294-gm male fetus in the emergency room. An autopsy disclosed no external or internal anomalies. The patient's two previous pregnancies had ended at 8 weeks and 26 weeks gestation; neither fetus had been examined histologically. Routine sections showed no inflammatory infiltrates. Culture of fetal viscera in BSK medium yielded *B. burgdorferi* and other bacteria from fetal kidney (Fig. 7), although no spirochetes were found in cultures of fetal brain, liver, spleen, heart, or thymus. No spirochetes were identified in fetal viscera using immunohistochemistry.

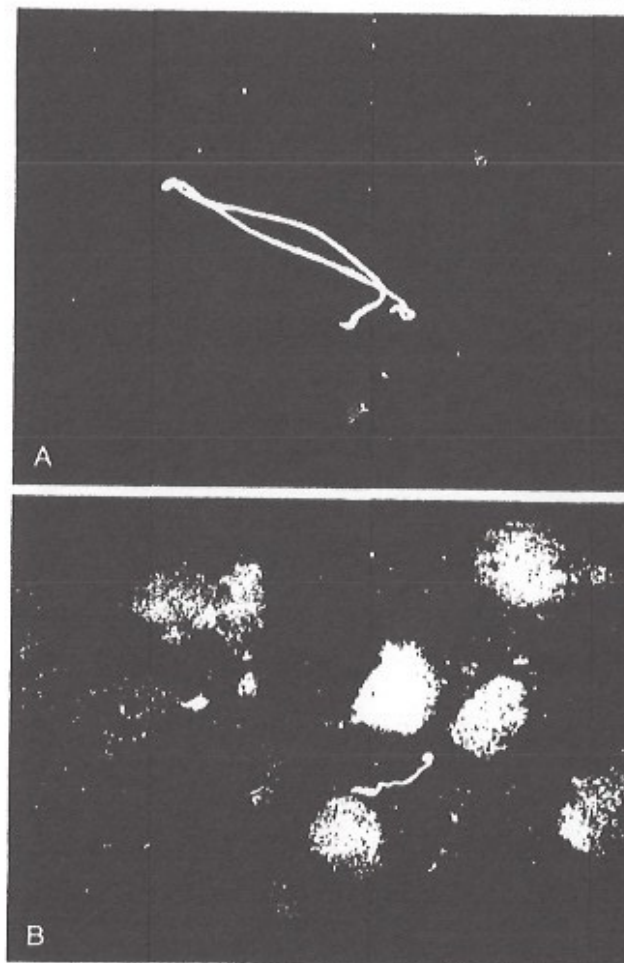


A



B

Figure 5. A, Fetal autopsy brain showing hydrocephalus. B, *B. burgdorferi*, indirect immunofluorescence, 1500X original magnification, imprint cytology monolayer from autopsy brain.



A

B

Figure 6. A, *B. burgdorferi*, indirect immunofluorescence, autopsy brain imprint preparation, 1500X original magnification. B, *B. burgdorferi*, indirect immunofluorescence, autopsy brain imprint preparation, 1500X original magnification.

#### Case 10: Fetal Lyme Borreliosis with Intrauterine Death at 25 Weeks Gestation

A 27-year-old black woman was admitted for induction of labor at 25 weeks gestation after a routine obstetric ultrasound examination confirmed that the fetus had died in utero. No high-risk factors were noted in the patient's prenatal care record and no infections were identified. The



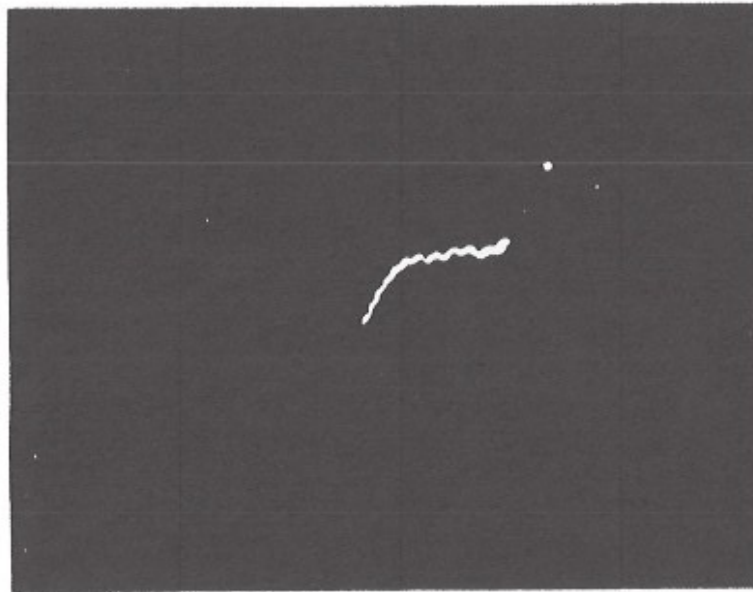

Figure 7. *Borrelia* species morphologically consistent with *B. burgdorferi*, darkfield microscope image 400X original magnification. Culture of autopsy fetal kidney in Barbour Stoenner Kelly medium.

patient reported in retrospect that she had experienced myalgias, arthralgias, and episode of headache for which she did not seek medical attention. A macerated male fetus showed no external anomalies at delivery. An autopsy showed a large intraventricular septal defect without additional internal anomalies. Postpartum Lyme serology performed on maternal blood was nonreactive. *B. burgdorferi* was identified in tissue by indirect immunofluorescence.

#### Case 11: Fetal Lyme Borreliosis Presenting as Neonatal Sepsis at Term Pregnancy

A 19-year-old black woman was admitted in January 1986 in active labor. She delivered an 8 lb 5 oz male infant who developed respiratory distress in the first hour of life and was transferred to a neonatal intensive care unit at a university hospital. Examination of the placenta revealed otherwise normal appearing villi which contained rare *B. burgdorferi* spirochetes (Fig. 8). The infant responded to intravenous antibiotic therapy.

#### Case 12: Fetal Borreliosis with Toxemia of Pregnancy and Neonatal Sepsis

A 26-year-old white woman was admitted in December 1985 at term pregnancy. Toxemia of pregnancy had its onset in week 37 of her

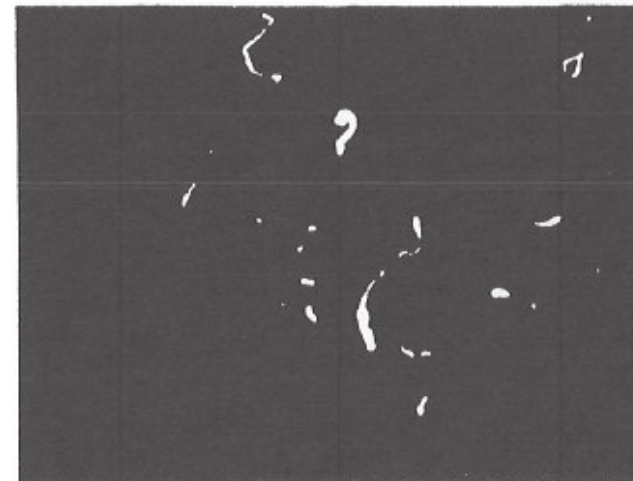


Figure 8. Various forms of *Borrelia* spirochetes including a small ring form, umbilical cord blood specimen, Indirect immunofluorescence, 1000X original magnification.

pregnancy and was manifested as hypertension and proteinuria. The infant weighed 4 lb 12 oz at delivery and appeared healthy and active in the delivery room. Respiratory distress ensued in the first day of life and was associated with hypoglycemia and fever. The infant was treated with intravenous penicillin and metronidazole for septicemia of unknown cause after routine bacteriology cultures yielded no pathogens. At the request of the attending pediatrician, the placenta was re-examined for spirochetes by Warthin starry silver impregnation. Many spirochetes were found in the placenta (Fig. 9). The infant is now 3 years old, and has shown normal growth and development. The mother has carried a second pregnancy to term and her second child is healthy.

#### Case 13: Maternal Lyme Borreliosis with Persistent Placental Spirochetosis Despite Oral Penicillin Therapy in Second Trimester

A 28-year-old white woman was admitted in November 1986 in active labor at term pregnancy. Lyme borreliosis had been diagnosed in her second trimester when erythema migrans was found on the skin of her back. She took 500 mg of oral penicillin VK for 15 days, and the erythema migrans lesion faded and disappeared in the eighth day of therapy. One month later she consulted a cardiologist because of complaints of dizziness. Sinus tachycardia was diagnosed by ambulatory cardiac monitoring. She delivered a healthy appearing 8 lb 13 oz male infant. Serology tests were negative for antibodies to *B. burgdorferi* in maternal blood and in umbilical cord blood from the infant by both IFA and ELISA methods. Culture of the placenta in BSK medium yielded motile spirochetes resembling borrelia species which could not be subcultured. Warthin starry silver impregnation yielded spirochetes in pla-



Figure 9. *B. burgdorferi*, various forms, placenta, 1000X original magnification, Warthin starry silver impregnation.

cental villi (Fig. 10). A retrospective interview disclosed that 2 weeks before delivery, the patient had sought medical attention because she noticed an Ixodid tick attached to her right leg. A 13 by 13 mm erythematous patch not consistent with erythema migrans was identified by her physician. Both mother and infant were retreated with oral penicillin plus probenecid after delivery. Neither patient developed a Herxheimer reaction. Mother and child appeared well in several follow-up visits.

#### Case 14: Maternal Lyme Borreliosis in Second Trimester of Pregnancy Followed by Toxemia of Pregnancy

A 23-year-old white woman was admitted to the hospital in her second trimester of pregnancy with concurrent erythema migrans and aseptic meningitis. Serology for Lyme disease was negative during the acute illness and remained negative in the convalescent period through term pregnancy. She was adequately treated with intravenous aqueous penicillin for 10 days. The erythema migrans lesion gradually disappeared by the third day of antibiotic therapy. The patient was closely monitored for the remainder of her pregnancy. In October 1986, 12 days before term, she was readmitted for mild toxemia of pregnancy presenting as hypertension which was treated with bedrest. She delivered a healthy male infant. Placental examination yielded no spirochetes by either culture or by histologic methods. Mother and child appeared well in serial follow-up postpartum visits.

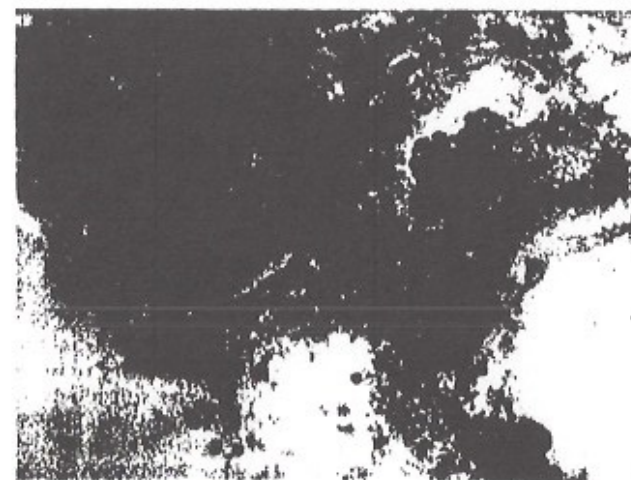


Figure 10. *B. burgdorferi* in placenta, 1500X original magnification, Warthin starry silver impregnation.



### RATIONALE FOR A PROSPECTIVE STUDY OF SUDDEN INFANT DEATH SYNDROME (SIDS)

Clinical and pathologic study of fetuses and infants with fetal borreliosis acquired in utero indicate that the expectations do not always correspond with the observations in the cohort. Three observations which accrue from the cases of fetal borreliosis are:

1. Tissue inflammation is absent in fetuses with transplacentally acquired *B. burgdorferi* infection.
2. Gestational Lyme borreliosis may be associated with fetal death in utero, fetal death at term, or infant death after birth.
3. Maternal blood is seronegative for specific antibodies against *B. burgdorferi* in cases where the spirochete can be demonstrated in the fetus or placenta.

Syphilis acquired in utero could in some cases present with death of the infant in the first year of life.<sup>8</sup> Some of the infants with prenatal syphilis who died showed no clinical evidence of the infection when they were delivered. These observations from the clinical experience with syphilis led the author to test the following hypothesis. Some cases of sudden infant death syndrome (SIDS) might be circumstantially associated with subclinical persistent *B. burgdorferi* infections which were acquired in utero.

Permission to study 10 cases of SIDS was obtained from the Chief Medical Examiner of Suffolk County, New York. All cases were certified as SIDS<sup>10</sup> using the strict criteria of forensic pathology, all cases had been thoroughly examined with a detailed autopsy, routine histology, and toxicology studies. A condition of the study was that strict patient confidentiality be maintained. Sections of the heart, brain, kidney, and liver were prepared and Warthin starry silver impregnation was performed. Two of the ten cases showed spirochetes morphologically consistent with *B. burgdorferi* in the infant brain; one of the cases was a male infant who had died suddenly at 4 months of age (Fig. 11); and the second was a female infant death at 4 months of age. Spirochetes were not identified in the representative sections from kidney, liver, or heart. No inflammation was identified in the microscopic fields which contained the spirochetes.

### SUMMARY

Great diversity of clinical expression of signs and symptoms of gestational Lyme borreliosis parallels the diversity of prenatal syphilis. It is documented that transplacental transmission of the spirochete from mother to fetus is possible. Further research is necessary to investigate possible teratogenic effects that might occur if the spirochete reaches the fetus during the period of organogenesis. Autopsy and clinical studies have associated gestational Lyme borreliosis with various medical problems including fetal death, hydrocephalus, cardiovascular anomalies, neonatal respiratory distress, hyperbilirubinemia, intrauterine growth retardation, cortical blindness, sudden infant death syndrome,




Figure 11. A, *Borrelia* species morphologically consistent with *B. burgdorferi*, 1750X, Warthin starry silver impregnation, autopsy brain, sudden infant death syndrome; infant age 4 months. B, *B. burgdorferi* reference strain B31, suspended in agar, Warthin starry silver stain, 1750X original magnification. C, *Borrelia* species morphologically consistent with *B. burgdorferi*, 1750X, Warthin starry silver impregnation, autopsy brain, sudden infant death syndrome; infant age 4 months. D, *B. burgdorferi* reference strain B31 suspended in agar, Warthin starry silver stain, 1750X original magnification.

and maternal toxemia of pregnancy. Whether any or all of these associations are coincidentally or causally related remains to be clarified by further investigation. It is my expectation that the spectrum of gestational Lyme borreliosis will expand into many of the clinical domains of prenatal syphilis.

### ACKNOWLEDGMENTS

The support of the Southampton Hospital Lyme Disease Research Fund and a gift from Mrs. C.E.H. are gratefully acknowledged. Dr. Bernard Berger and Dr. John E. Hunt Jr. generously provided information for some of the clinical case studies. Dr. J. Lawton Smith and Dr. Eliot Goldings encouraged the author in this undertaking.

### REFERENCES

1. Barbour AG: Laboratory aspects of Lyme borreliosis. Clin Microbiol Rev 4:399-414, 1988

2. Dattwyler RG, Volkman DJ, Luft BJ: Seronegative Lyme disease, dissociation of specific T and B Lymphocyte responses to *Borrelia burgdorferi*. *N Engl J Med* 319:1441-1446, 1988
3. Lavoie PE, et al: Culture positive seronegative transplacental Lyme borreliosis infant mortality. *Arthritis Rheum* 3(Suppl):S50, 1987
4. MacDonald AB, Benach JL, Burgdorfer W: Stillbirth following maternal Lyme disease. *NY State J Med* 87:615, 1987
5. MacDonald AB: Human fetal borreliosis, toxemia of pregnancy, and fetal death. *Zentralblatt Bakt Hygiene* 263:189-200, 1986
6. Markowitz LE, Steere AC, Benach JL, et al: Lyme disease during pregnancy. *JAMA* 255:3394-3396, 1986
7. Schlesinger PA, Duray PH, Burke BA, et al: Maternal fetal transmission of the Lyme disease spirochete *Borrelia burgdorferi*. *Ann Intern Med* 103:67-68, 1985
8. Stokes JH, et al: *Modern Clinical Syphilology*, ed 3. Philadelphia, WB Saunders, 1945
9. Weber K, Bratzke HJ, Neubert U, et al: *Borrelia burgdorferi* in a newborn despite oral penicillin for Lyme borreliosis during pregnancy. *Pediatr Infect Dis J* 7:286-289, 1988
10. Wigglesworth JL: *Perinatal Pathology*. Philadelphia, WB Saunders, 1984
11. Williams CL, Benach JL, Curran AS, et al: Lyme disease during pregnancy: A cord blood study. *Ann NY Acad Sci* 539:504-506, 1988

Department of Pathology  
Southampton Hospital  
Southampton, NY 11968