

Functional Brain Imaging and Neuropsychological Testing in Lyme Disease

Brian A. Fallon, Sam Das, Jeffrey J. Plutchok,
Felice Tager, Kenneth Liegner, and Ronald Van Heertum

From The New York State Psychiatric Institute, the Department of Psychiatry of Columbia University and Columbia-Presbyterian Medical Center, and the Department of Nuclear Medicine of Columbia-Presbyterian Medical Center, New York, New York; and private practice in Armonk, New York

Differentiating neuropsychiatric Lyme disease from a primary psychiatric disorder can be a daunting task. This article describes how functional brain imaging and neuropsychological testing can be particularly valuable in helping to make diagnostic distinctions. In addition to a review of the relevance of functional imaging to neuropsychiatry in general, recent findings are presented regarding the use of single photon emission computed tomographic (SPECT) imaging in Lyme disease.

Primary care physicians and medical specialists are increasingly being asked to evaluate patients whose primary diagnosis may be either Lyme disease or a psychiatric disorder. Differentiating the two can be difficult at times, particularly because the manifestations of Lyme disease include secondary neuropsychiatric disorders [1]. Patients with Lyme disease may experience short-term memory loss, severe depression, panic attacks, unrelenting anxiety, impulsivity, paranoia, obsessive compulsive disorder, personality changes marked by irritability and mood swings, and, rarely, manic episodes or psychotic states. Depression of at least 2 weeks' duration, by far the most common concomitant secondary psychiatric disorder, may occur in as many as 70% of patients with chronic Lyme disease at some point during their illness [2].

The suggestion that these states are related to the Lyme infection is based on three findings: the frequency of psychiatric disorders is greater among patients with Lyme disease than among those with other medical conditions [2]; patients' psychiatric disorders may improve with antibiotic treatment alone [3]; and many patients who developed these neuropsychiatric conditions reported being psychiatrically healthy prior to the onset of Lyme disease [1].

Lyme disease is not the only medical illness that can have psychiatric manifestations. Others include syphilis, AIDS, viral pneumonia, carcinoma of the brain or pancreas, hypoxia, endocrinopathies, vitamin B12 or folate deficiencies, temporal lobe epilepsy, Wilson's disease, and collagen vascular diseases such as systemic lupus erythematosus. Failure to recognize the medical abnormality underlying what appears to be a "classic" psychiatric disorder is not uncommon. Koranyi [4] reported that nearly one-fifth of a sample of psychiatric outpatients had

a medical condition as the cause of their psychiatric disorder and that this physical condition had been missed by the referring physician in about one-third of the cases.

Research indicates that when a doctor is frustrated by a patient, either because of the lack of a laboratory test to definitively make a diagnosis or because of a poor response to the physician's therapeutic interventions, the physician is then more likely to call the patient a hypochondriac [5]. Patients with irritable bowel syndrome, chronic fatigue syndrome, and chronic Lyme disease may be mislabeled as having hypochondriasis or somatization disorder [6, 7]. Such mislabeling may have particularly detrimental effects on the Lyme disease patient, as a delay in diagnosis and treatment may result in a curable acute infection becoming a chronic, treatment-refractory illness.

In some cases, because of the marked debility that can be caused by chronic Lyme disease, failure to diagnose has led to malpractice litigation. Physicians should therefore consider Lyme disease in the differential diagnosis of any psychiatric disorder of new onset, particularly if there are atypical features.

While mislabeling Lyme disease as a primary psychiatric disorder can be damaging, so too can incorrectly labeling a primary psychiatric disorder as Lyme disease. Patients may then be exposed to unnecessary antibiotic treatment and possible secondary superinfection. Of equal concern is that comprehensive psychiatric care may be delayed because patients fear that seeking mental health care will result in their being stigmatized as a "crock" or a mentally ill patient. Tragic consequences may result. Major depression, for example, results in completed suicide in 15% of cases [8].

To aid the clinician in the task of differentiating Lyme disease from primary psychiatric disorders, this article will focus on four aspects of the evaluation that can be particularly helpful: clinical presentation, laboratory testing, neuropsychological testing, and functional brain imaging.

The Clinical Presentation

Differentiation between the emotional and cognitive abnormalities due to Lyme disease and those of a primarily psycho-

Presented in part at the International Conference on Lyme Borreliosis (Boston), 1996.

Reprints or correspondence: Dr. Brian A. Fallon, The NYS Psychiatric Institute, 722 West 168th Street, No. 13, New York, New York 10032.

Clinical Infectious Diseases 1997;25(Suppl 1):S57-63
© 1997 by The University of Chicago. All rights reserved.
1058-4838/97/2501-0008\$03.00

logical etiology may be aided by the following considerations. First, does the patient have markers of a nonpsychiatric disease, such as an erythema migrans rash, arthralgias or arthritis, myalgias, severe headaches, increased sound or light sensitivity, paresthesias, diffuse fasciculations, cardiac conduction delay, word-finding problems, short-term memory loss, cranial neuropathies, and/or radicular or shooting pains [9]?

Second, is the psychiatric disorder itself unusual? For example, in the case of depression, is it characterized by marked mood lability, in which the patient bursts into tears for no apparent reason or in which moods fluctuate from normal to extreme irritability over short periods? In the case of panic disorder, does the acute anxiety last longer than the usual 10-minute interval characteristic of most primary panic attacks?

Third, does the patient show a poor response to medications that typically would be helpful or that previously had helped that same patient? Fourth, is the psychiatric disorder of new onset in a person with no new identifiable stressors or secondary gain? Lack of a psychological precipitant for a psychiatric disorder of new onset should raise the possibility of an underlying medical illness.

Fifth, is there a history of a psychiatric disorder or a strong family history of psychiatric disturbances, such that the patient's current condition may be unrelated to Lyme disease, exacerbated by Lyme disease, or triggered but not perpetuated by Lyme disease? As a general rule, whenever a patient older than the age of 40 years develops a psychiatric disorder for the first time without apparent cause, an organic etiology must be suspected.

Laboratory Tests

Laboratory testing is an essential component of the diagnostic assessment, both to provide evidence of exposure to *Borrelia burgdorferi* and to exclude other diseases that might have neuropsychiatric presentations, such as systemic lupus erythematosus, multiple sclerosis, vitamin deficiencies, and endocrinopathies. The ELISA and the western blot are the most commonly employed indirect serological tests. Although these tests are extremely helpful in confirming Lyme disease when both tests give evidence of reactivity, these tests can be misleading when equivocal results are obtained.

For example, some patients with Lyme disease may have western blot results that indicate the presence of only a few of the bands that the Centers for Disease Control and Prevention (CDC) considers specific for Lyme disease—i.e., the results are suggestive of Lyme disease but do not meet the standard of five bands required by the CDC for a positive western blot and are therefore interpreted as “nonreactive.” For some such patients, additional bands may become evident after treatment [10].

Others may have meaningful evidence of exposure to *B. burgdorferi*, such as reactivity at the highly specific 31 kD (OspA) and 34 kD (OspB) sites. Unfortunately, because these

bands are not included in the CDC's top 10 list of diagnostic bands, many laboratories will not report them and therefore fail to provide the clinician with all of the important data. In the absence of definitive indirect diagnostic tests, additional testing that more directly detects the presence of the spirochete may be helpful.

The PCR assay for *B. burgdorferi*, if done at a reputable laboratory with good quality-control standards, may detect the presence of the DNA and therefore suggest active infection [11]. The Lyme urine antigen test, in the absence of a concurrent urinary tract infection, may be helpful in detecting the presence of *B. burgdorferi* protein shedding [12]; however, more research needs to be conducted regarding both the sensitivity and specificity of this test. Critical to proper interpretation of serological testing is that the tests be done at laboratories that have excellent quality control and high levels of sensitivity and specificity.

Tests of other involved areas, such as the CSF and joint cavities, are also essential components of a thorough evaluation. In chronic neuropsychiatric Lyme disease, a Lyme ELISA of the serum may not always be sufficiently sensitive to detect disease, as suggested by a recent study in which 22% of patients had negative whole sonicated *B. burgdorferi* ELISAs despite having culture- or PCR-proven disease [13].

Although CSF studies in early neurological Lyme disease are often abnormal, with evidence of intrathecal antibody production in 70%–90% of cases of Lyme meningitis, routine CSF antibody studies in chronic Lyme encephalopathy may be misleadingly normal. In a study of 35 patients with late neurological Lyme disease who had *B. burgdorferi* OspA antigen in the CSF on experimental testing, 43% had normal CSF antibody study results and 20% had no evidence of either Lyme antibodies or other typical CSF abnormalities [14]. Normal CSF results therefore cannot be used to rule out neuroborreliosis.

Neuropsychological Testing

Patients with Lyme encephalopathy present with recent memory, word-finding, and spatial disorientation problems, make dyslexic-like number reversals or letter reversals when writing, and are markedly distractible, such that they have trouble staying focused and completing projects. Often accompanied by a family member who acts as a surrogate memory source, such patients easily get confused, may forget key experiences, or may go off on a tangent and be unable to recall the initial question.

On neuropsychological tests, 50%–60% of patients with chronic neurological Lyme disease have evidence of objective impairment [15, 16]. The impairment may involve memory, attention and concentration, verbal fluency, perceptual motor functioning, and/or conceptual ability. Often, objective cognitive deficits on neuropsychological testing can be demonstrated despite normal findings from a neurological examination and of electroencephalographic, CSF, and MRI studies [16, 17].

While a patient may not appear to have memory problems on a routine clinical evaluation, clinically significant abnormalities may be evident on formal neuropsychological testing. Such tests, then, are valuable both as a means of confirming the presence of objective impairment and as a baseline from which to measure subsequent response to treatment. Tests that are particularly helpful include the Wechsler Memory Scale, the Buschke Selective Reminding test, and the Controlled Oral Word Association test. Patients with Lyme encephalopathy have significantly more memory problems than patients with other disorders that share certain features with Lyme disease, such as fibromyalgia or mild depression [18].

Fatigue, anxiety, and depression, however, can cause a patient to perform poorly on neuropsychological tests. The psychiatric disorder itself may be primary—i.e., unrelated to the biology of Lyme disease—or secondary to the pathophysiological processes induced by *B. burgdorferi*. Regardless of whether the psychiatric disorder is primary or secondary, it behooves the physician to treat the concomitant psychiatric disorder aggressively in order to optimize the patient's functioning and more clearly evaluate the need for additional antibiotic treatment.

In most cases, adjunctive antidepressant treatment, for example, will result in greater mood stability, less despair, and consequently a greater ability to participate actively in the process of recovery. In the presence of active infection, however, psychiatric disorders related to CNS Lyme disease may be resistant to psychopharmacological treatment but may respond to such treatment following adequate antibiotic therapy.

Are neuropsychological tests helpful in differentiating Lyme encephalopathy from primary anxiety and depression? In cases of memory loss accompanied by mild depression, neuropsychological testing can be extremely valuable. Typically, mildly depressed patients will show few if any objective memory deficits on neuropsychological testing, while patients with Lyme encephalopathy will show mild to severe levels of impairment, particularly in verbal fluency and verbal short-term memory.

When neuropsychological tests do reveal deficits among depressed patients, the deficits may occur because of lack of effort and poor concentration rather than actual deficits in storage or retrieval. Depressed patients tend to give up easily when tested, responding "I don't know," whereas patients with primary memory disorders such as in Alzheimer's disease more commonly make a determined effort but give incorrect answers [19]. Depressed patients tend to have good automatic or incidental learning (e.g., recalling what they had for breakfast or recalling the day of the week), whereas encephalopathic patients more typically have poor automatic learning.

In a study of 15 patients with chronic Lyme disease and memory complaints, 9 had abnormal neuropsychological test results, while 6 had normal scores [16]; 5 of the 6 cognitively normal patients had the highest depression scores of the entire group of 15, confirming that moderate depression causes the

perception of memory problems in some patients who do not have evidence of objective impairment. These moderately depressed patients, if treated for their psychiatric problem, would likely experience an improvement of both mood and cognition.

As depression becomes more severe, however, neuropsychological tests may show impairment in many cognitive areas. The deficits in moderately to severely depressed patients typically involve spatial and holistic tasks, as well as tasks that require speed or sustained motor effort [20]. In addition, deficits may be seen on intelligence tests and in verbal learning and free recall [21]. Therefore, to get the most information from a set of neuropsychological tests, the clinician would be wise to treat a patient's concomitant mood disorder prior to initiation of the testing, thereby removing a confounding variable in test interpretation.

Functional Brain Imaging

Neuroimaging provides a direct window into the brain's structure and functioning. Structural imaging techniques, such as CT and routine MRI, are used primarily to evaluate anatomy, providing a highly detailed but static image of brain structure. Functional brain imaging techniques, such as single photon emission computed tomography (SPECT) and positron emission tomography (PET), provide a dynamic picture of the brain's functioning: metabolism, blood flow, and chemistry. While structural imaging techniques are very helpful in identifying gross changes in brain structure, functional imaging techniques allow us to appreciate the working physiology of the brain.

PET studies have confirmed that regional cerebral blood-flow changes are generally coupled with changes in regional brain metabolism. Decreased metabolic activity results in hypoperfusion, whereas increased metabolic activity results in hyperperfusion. Although hypoperfusion may occur as a result of vascular changes, functional brain imaging is particularly valuable to neuropsychiatrists for its ability to detect changes in perfusion that are secondary to metabolic changes. In comparison to PET scanning, SPECT scanning is about 3–4 times less expensive, is more widely available, and with the more recent SPECT scanners is able to provide spatial resolution images of 6–9 mm—closely approaching the 4–6-mm resolution of PET studies.

SPECT scanners typically use a rotating gamma camera gantry with one to three detector heads. The image data are subsequently reconstructed and reoriented in three orthogonal (coronal, sagittal, and transaxial) image planes. Although PET imaging can be used to provide a quantitative assessment of regional perfusion or metabolic abnormalities, the technique is invasive, requiring arterial sampling. To avoid the necessity of arterial sampling, the analysis of PET and SPECT scans is best done in a semiquantitative fashion.

MRI scans of patients with neurological Lyme disease may demonstrate punctate white matter lesions on T₂-weighted

images, similar to those seen in demyelinating disorders, such as multiple sclerosis [17]. This is most often the case among patients with evidence of meningitis or encephalitis. The white matter lesions may resolve after antibiotic treatment. In later-stage neurological Lyme disease, however, brain MRI scans are generally normal even though the patient may continue to have debilitating neuropsychiatric problems [22].

Functional brain imaging by means of SPECT has recently emerged as a new and very useful tool in the evaluation of patients with Lyme disease. In patients with Lyme disease, SPECT scans typically show multifocal areas of decreased perfusion in both the cortex and the subcortical white matter [23–27]. In a review of 35 patients consecutively referred to Columbia Presbyterian Medical Center (New York) for technetium-99m SPECT imaging who were suspected of having neurological sequelae to Lyme disease, 18 (51.4%) had significant perfusion abnormalities [25].

Of these 18 patients, 17 had regional cortical abnormalities, 15 had a heterogeneous pattern of uptake, 14 had reduced tracer uptake in the periventricular white matter, and 11 had a global reduction of cortical perfusion. Most commonly involved were the frontal, temporal, and parietal lobes. Among the 18 patients whose SPECT scans were abnormal, 13 had normal brain MRI studies. A significant limitation of this study [25] is that patients were not prospectively categorized according to the diagnostic certainty of Lyme disease. Because all patients, including those with probable but not definite Lyme disease, were grouped together, the findings from this report must be considered tentative.

In a more recent report from investigators at Columbia [27], 20 patients with seropositive chronic Lyme disease who had been previously treated with antibiotics were evaluated by technetium-99m-HMPAO (hexamethylpropyleneamineoxime) SPECT before and after repeated antibiotic treatment. The two scans of each patient with Lyme disease were read in random order by radiologists blind to the treatment received and to the temporal order of scans. The scans of 14 patients with non-Lyme neurological or systemic disease were interspersed so that radiologists would be blind to diagnosis as well.

Ninety-six percent (27) of the 28 abnormal Lyme SPECT images showed a heterogeneous pattern, but this pattern was non-specific, as it was also seen in the control patients with Creutzfeldt-Jakob disease, cerebral vasculitis, and chronic fatigue syndrome. Forty-one percent of the Lyme scans showed improved perfusion on the second scan, with the suggestion of more improvement among patients treated with iv antibiotics (5 of 10) than among patients given other forms of treatment (2 of 7).

In an abstract consistent with the above findings of a heterogeneous pattern of uptake, Logigian et al. [23] reported on eight patients with seropositive Lyme disease who were studied with use of the more objective quantitative SPECT method. All had reduced perfusion in a multifocal distribution, especially in the white matter. Only one of the eight had MRI white-matter abnormalities. Six of the eight had abnormal spinal fluid, of whom three had intrathecal antibody production. All had neuro-

psychological deficits of verbal and visual memory. Six months following iv antibiotic treatment, quantitative SPECT scans of five of the patients revealed a pattern of improved flow.

In a more recent report [24], Logigian contrasted the brain perfusion patterns of 13 patients with definite Lyme encephalopathy (as defined by the presence of objective deficits on neuropsychological testing), 9 patients with possible Lyme encephalopathy (no objective deficits), and 26 normal controls. Patients with definite Lyme encephalopathy had significantly more deficits than patients with possible encephalopathy, who in turn had significantly more deficits than normal controls.

When the 13 patients with definite Lyme encephalopathy were given iv ceftriaxone, a partial reversal in brain perfusion deficits was observed 6 months later. These results suggest that SPECT perfusion deficits are greater with more severe disease, that SPECT deficits may be seen even in the absence of objective neuropsychological deficits, and that the perfusion deficits are at least partially reversible.

Hypoperfusion defects visualized on SPECT scans in Lyme disease may result from any process that alters the radiotracer distribution, including vascular delivery to neurons, transport of the tracer into the cells, and retention of the radioactive tracer in the cells. Problems may arise secondary to direct infection of neurons, from cellular dysfunction due to the indirect effects of neurotoxic immunomodulators such as cytokines, or from decreased perfusion through arterioles secondary to vasculitis. In other words, areas of hypoperfusion may result from a cellular, metabolic, and/or vascular problem.

In what ways, then, are SPECT scans helpful in the diagnostic assessment? First, a SPECT scan with diffuse abnormalities may help to confirm that an objective abnormality is present in a patient suspected of having a purely factitious or psychogenic disorder. Second, a normal SPECT scan of a patient with prominent neuropsychiatric symptoms may suggest that a psychiatric disorder is the primary cause of the patient's cognitive or emotional distress and therefore lead the clinician to recommend reevaluation of the patient's psychiatric treatment. Third, an improvement in SPECT perfusion after treatment provides evidence that the brain has not been permanently damaged and that the treatments are resulting in physiological change.

Consider the following case. A 27-year-old previously healthy man who lived in an area of hyperendemicity for Lyme disease developed intense fatigue and intermittent paranoid delusions that he was being followed. Over the subsequent months, headaches, memory lapses, mental "cloudiness," and episodic inability to perform routine activities emerged. Cognitive deterioration advanced such that he no longer recognized members of his own family.

After admission to an intensive care unit and a full battery of tests, the diagnosis of CNS Lyme disease was made on the basis of positive ELISAs of the serum and CSF (0.267 and 0.265 optical density, respectively; cutoff, 0.112 optical density) and mild pleocytosis (6 WBCs/mm³). Results of MRI and electroencephalography were normal. After treatment for

3 weeks with iv ceftriaxone, he was able to identify his family and friends and wished to return to work. However, over the subsequent few weeks after further iv antibiotic therapy had been discontinued, his confusion and memory problems returned (he would get lost in his own house), and new symptoms appeared: swollen knees, arthralgias in his toes and hands, and numbness on his right side.

Upon return to the infectious disease specialist, the patient and his family were told that his symptoms were probably not due to Lyme disease because he had already received the recommended course of treatment. A second spinal tap again showed pleocytosis (6 WBCs/mm³), but the Lyme serologies, performed at a different laboratory, were now negative. Nevertheless, in response to pressure from the family and differing opinions from other specialists, this man was retreated for 2 more weeks with iv antibiotics. This time his condition did not improve.

A team of psychiatrists evaluated the patient and concluded that he had a "dissociative disorder" rather than Lyme disease and should be transferred to a psychiatric inpatient facility. At this point, unable to feed himself or to speak coherently, he was removed from the care of the hospital by his family, who had arranged for him to be treated privately. Four months after discharge, a brain SPECT scan was done. Although clinically able to feed himself, he still had severe cognitive deficits; he did not know his name or any details of the prior year.

Was this a dissociative disorder? See figure 1, which compares this man's SPECT scan to the scan of a patient with no abnormalities. The SPECT scan of the patient with Lyme disease revealed marked hypoperfusion throughout the cortex as well as the appearance of dilated ventricles. Because this patient had a normal MRI scan with no evidence of structural abnormalities such as dilated ventricles, it was concluded that the SPECT image indicated gray matter perfusion deficits as well as prominent white matter deficits, which gave the appearance of a dilated ventricle because the radiotracer deposition was so markedly reduced in the periventricular area. The SPECT scan findings were more consistent with a medical disease diffusely affecting brain function rather than a primary dissociative disorder, as the latter does not typically cause profound perfusion deficits.

It should be emphasized that the absence of perfusion abnormalities on a SPECT or PET scan does not prove absence of a disease process. As has been shown in studies of Alzheimer's disease, during the early stages of the illness, 45% of patients will not have perfusion abnormalities [28]. In Lyme disease, therefore, a normal SPECT scan may indicate that either the brain is not involved or the brain involvement is in its early stages or resolving.

In order to better appreciate the utility of SPECT imaging, a brief review of patterns of perfusion seen in other areas of clinical neuropsychiatry is required. Familiarity with these patterns may enable one to more clearly state that a patient's neuropsychiatric disorder is primarily psychiatric or secondary

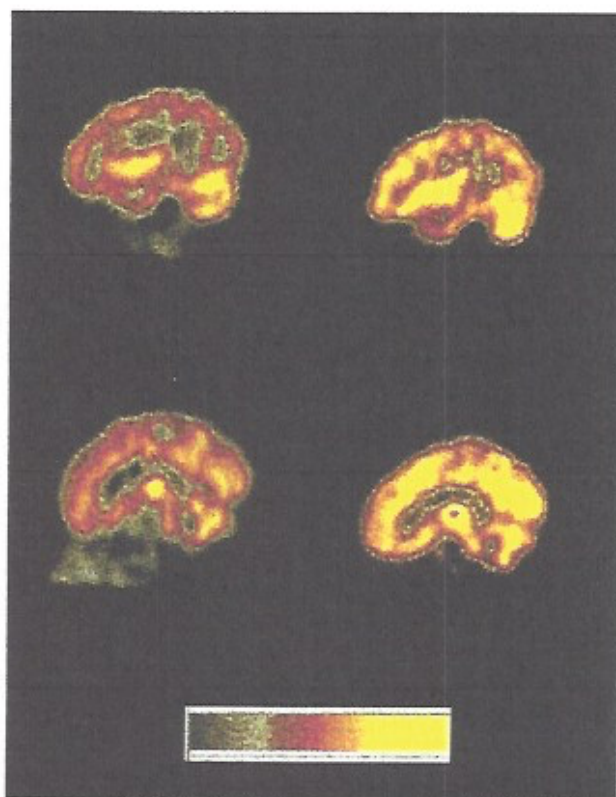


Figure 1. Sagittal views obtained with technetium-99m HMPAO SPECT. The two views on the left are of the patient with severe Lyme encephalopathy. The views on the right are of a patient with no abnormalities and demonstrate a normally perfused scan. The color spectrum scale, from gray to yellow, represents low to normal perfusion.

to another illness. For example, the pattern of primary depression is different from the pattern of Alzheimer's dementia and from that of CNS Lyme disease. Although clinical judgment must still take precedence in the evaluation of the patient, these functional imaging techniques can substantially improve diagnostic confidence.

In primary depression, one most commonly sees decreased uptake in the left anterolateral prefrontal cortex and, less commonly, decreased flow in the temporal lobes [29]. Left-frontal-lobe normalization of flow may occur after successful treatment of depression [30, 31]. This pattern of decreased frontal blood flow commonly seen in primary depression is also typical of depression secondary to other illnesses, such as Parkinson's disease, Huntington's chorea, epilepsy, HIV dementia, and, presumably, Lyme disease. Nevertheless, in Lyme disease accompanied by depression, as in most medical conditions with secondary depression, one would expect to see abnormal perfusion extending beyond the frontal lobe areas as well.

In early Alzheimer's disease, one typically sees decreased flow in the temporal and posterior parietal areas, with sparing of the sensorimotor strip and occipital cortex, while in later Alzheimer's disease the frontal lobe may also be involved

[32, 33]. Temporoparietal abnormalities may be evident on functional imaging before atrophy is seen on CT or MRI scans. This pattern of temporoparietal hypoperfusion distinguishes Alzheimer's disease from several other dementing illnesses, such as AIDS-dementia complex, which shows a more diffusely heterogeneous pattern, and depressive pseudodementia, which tends to localize to the frontal lobes [34]. A parietal hypoperfusion pattern, however, overlaps with Parkinson's disease dementia and, as seems to be true from our xenon¹³³ SPECT studies (Fallon, 1996; unpublished data), with Lyme disease-related memory problems.

In early Huntington's disease, one may see decreased flow in the caudate nucleus, putamen, and cingulate gyrus by means of PET scanning [35]. Similarly, SPECT imaging has revealed markedly decreased flow in the caudate [36].

Psychiatric disorders other than depression may also have characteristic functional imaging patterns. In obsessive compulsive disorder, functional imaging studies may show increased flow in the frontal cortex and the caudate [37]. In schizophrenia, patients with positive symptoms (delusions, hallucinations) may have temporal lobe hypoperfusion, while patients with negative symptoms (amotivation, flat affect) may have frontal lobe hypoperfusion [38, 39].

Therefore, in evaluating a depressed patient who presents with equivocal Lyme serologies but a clinical picture suggestive of Lyme disease, a SPECT scan may be very helpful. If the SPECT scan shows either a global reduction in flow or diffuse areas of heterogeneous tracer uptake, then this scan indicates that another physiological process, in addition to or instead of that which causes depression, is involved. Assuming that other medical causes of globally or heterogeneously reduced tracer uptake have been ruled out, then the diagnosis of Lyme disease is further supported but not necessarily confirmed.

One cannot conclude from a SPECT scan that a patient has Lyme disease, as similar SPECT scan patterns may be seen with other diseases as well. However, the diffusely abnormal SPECT scan does alert the clinician to the presence of an organic etiology other than that which causes primary depression.

Other disease processes that may cause a brain SPECT scan to show patchy, heterogeneous tracer uptake include vascular dementia [40, 41], chronic fatigue syndrome [42], CNS lupus [43], HIV encephalopathy [44, 45], and chronic or acute stimulant abuse [46]. Studies have shown, for example, that the SPECT scans of patients with AIDS dementia complex could not be differentiated from the SPECT scans of patients who were chronic cocaine abusers [46]. Therefore, in the interpretation of a SPECT scan that has revealed heterogeneous uptake, the above disorders certainly need to be considered.

Although there are important correlations between abnormalities in the clinical presentation and abnormal SPECT findings, it is not clear how closely improvements in clinical functioning are paralleled by improvements in brain perfusion. For example, it is known that metabolic or flow defects may persist after a stroke or trauma, despite normal neurological examina-

tion findings [32]. Our clinical experience with Lyme disease patients indicates that improvement in SPECT perfusion abnormalities may occur rapidly or lag behind clinical improvement by many months [26].

Conclusion

Physicians challenged with difficult differential neuropsychiatric diagnoses will benefit from employing an approach in which the clinical presentation and history are primary and other modalities are used to test the clinical impression. These additional modalities include laboratory testing of the serum and CSF, neuropsychological testing, and neuroimaging procedures.

SPECT scans, in their ability to detect diffuse cerebral abnormalities in the absence of other objective findings, such as an abnormal CSF, MRI, or focal neurological signs, may be particularly helpful in the process of differentiating neuropsychiatric Lyme disease from primary psychiatric disorders.

References

1. Fallon BA, Nields JA. Lyme disease: a neuropsychiatric illness. *Am J Psychiatry* 1994;151:1571-83.
2. Fallon BA, Nields JA, DelBene D, Saoud J, Wilson K, Liebowitz MR. Depression and Lyme disease: a controlled survey [abstract no NR119]. In: New research program and abstracts of the 144th Annual Meeting of the American Psychiatric Association. Washington, DC: American Psychiatric Association, 1991:76.
3. Pachner AR, Duray P, Steere AC. Central nervous system manifestations of Lyme disease. *Arch Neurol* 1989;46:790-5.
4. Koranyi EK. Somatic illness in psychiatric patients. *Psychosomatics* 1980;21:887-91.
5. Barsky AJ, Wyshak G, Latham KS, Klerman GL. Hypochondriacal patients, their physicians, and their medical care. *J Gen Intern Med* 1991;6:413-9.
6. Johnson SK, DeLuca J, Natelson BH. Assessing somatization disorder in the chronic fatigue syndrome. *Psychosomatic Medicine* 1996;58:50-7.
7. Noyes R, Kathol RG, Fisher MM, Phillips BM, Suelzer MT, Holt CS. The validity of DSM-III-R hypochondriasis. *Arch Gen Psychiatry* 1993;50:961-70.
8. Wilner A, Wilner L, Fishman R. Psychiatric adolescent inpatients: 8-10 year follow-up. *Arch Gen Psychiatry* 1979;36:698-700.
9. Fallon BA, Nields JA, Burrascano JJ, Liegner K, DelBene D, Liebowitz MR. The neuropsychiatric manifestations of Lyme borreliosis. *Psychiatric Quarterly* 1992;63:95-117.
10. Fein LA. Multivariate analysis of 160 patients with Lyme disease [abstract]. In: Program and abstracts of the 9th Annual International Conference on Lyme Borreliosis and Other Tick-Borne Disorders. Boston: Lyme Disease Foundation, 1996.
11. Keller TL, Halperin JJ, Whitman M. PCR detection of *Borrelia burgdorferi* DNA in cerebrospinal fluid of Lyme neuroborreliosis patients. *Neurology* 1992;42:32-42.
12. Harris NS, Stephens BG. Detection of *Borrelia burgdorferi* antigen in urine from patients with Lyme borreliosis. *Journal of Spirochetes and Tick-Borne Diseases* 1995;2:37-41.
13. Oksi J, Uksila J, Marjam AM, Nikoskelainen J, Viljanen MK. Antibodies against whole sonicated *Borrelia burgdorferi* spirochetes, 41-kilodalton flagellin and P39 protein in patients with PCR- or culture-proven late Lyme borreliosis. *J Clin Microbiol* 1995;33:2260-4.

14. Coyle PK, Schutzer SE, Deng Z, et al. Detection of *Borrelia burgdorferi*-specific antigen in antibody-negative cerebrospinal fluid in neurologic Lyme disease. *Neurology* 1995;45:2010-5.
15. Logigian EL, Kaplan RF, Steere AC. Chronic neurologic manifestations of Lyme disease. *N Engl J Med* 1990;323:1438-44.
16. Krupp LB, Masur D, Schwartz J, et al. Cognitive functioning in late Lyme borreliosis. *Arch Neurol* 1991;48:1125-9.
17. Halperin JJ, Pass HL, Anand AK, Luft BJ, Volkman DJ, Dattwyler RJ. Nervous system abnormalities in Lyme disease. *Ann NY Acad Sci* 1988;539:24-34.
18. Kaplan RF, Meadows ME, Vincent LC, Logigian EL, Steere AC. Memory impairment and depression in patients with Lyme encephalopathy: comparison with fibromyalgia and non-psychotically depressed patients. *Neurology* 1992;42:1263-7.
19. McGlynn SM, Kaszniak AN. When metacognition fails: impaired awareness of deficit in Alzheimer's disease. *J Cog Neuroscience* 1991;3:183-9.
20. Weingartner H, Silberman E. Models of cognitive impairment: cognitive changes in depression. *Psychopharmacology Bulletin* 1982;18:27-42.
21. Miller WR. Psychologic deficits in depression. *Psychological Bulletin* 1975;82:238-60.
22. Coyle PK. Neurologic Lyme disease. *Semin Neurol* 1992;12:200-8.
23. Logigian EL, Johnson KA, Kijewski MF, Kaplan RF, Holman BL, Steere AC. Cerebral hypoperfusion in Lyme encephalopathy: a quantitative SPECT study [abstract no P088T]. In: Program and abstracts of the 6th International Congress on Lyme Borreliosis (Bologna, Italy). 1994.
24. Logigian EL, Johnson KA, Kijewski MF, et al. Reversible cerebral hypoperfusion in Lyme encephalopathy as demonstrated by quantitative single photon emission computed tomography (SPECT) [abstract no D612]. In: Program and abstracts of the 7th International Congress on Lyme Borreliosis (San Francisco). 1996:134.
25. Das S, Plutchok J, Liegner KB, Fallon BA, Fawcuz RA, Van Heertum RL. TC-99m HMPAO brain SPECT detection of perfusion abnormalities in Lyme disease patients with clinical encephalopathy [abstract no 50762]. In: Program and abstracts of the 43rd Annual Meeting of the Society of Nuclear Medicine (Denver). 1996.
26. Liegner KB, Agricola MD, Fallon BA, Das S. Serial brain SPECT scanning with TC-99m HMPAO in patients with chronic Lyme encephalitis and encephalopathy undergoing prolonged intravenous antibiotic treatment [abstract no D626]. In: Program and abstracts of the 7th International Congress on Lyme Borreliosis (San Francisco). 1996:149.
27. Plutchok JJ, Tikofsky RS, Liegner KB. Serial brain SPECT imaging in chronic Lyme encephalopathy [abstract no 34735]. In: Program and abstracts of the 44th Annual Meeting of the Society of Nuclear Medicine (San Antonio). 1997.
28. Jagust WJ. Functional imaging in dementia: an overview. *J Clin Psychiatry* 1994;55(11, suppl):5-11.
29. Mayberg HS, Jeffery PJ, Wagner HN, et al. Regional cerebral blood flow in patients with refractory unipolar depression measured with Tc-99m HMPAO SPECT [abstract]. *J Nucl Med* 1991;32:951.
30. Baxter LR, Schwartz JM, Phelps ME, et al. Reduction of prefrontal cortex glucose metabolism common to three types of depression. *Arch Gen Psychiatry* 1989;46:243-50.
31. Dube S, Dobkin JA, Bowler KA, et al. Cerebral perfusion changes with antidepressant response in major depression. *Biol Psychiatry* 1993;33:47A-40.
32. Mayberg HS. Clinical correlates of PET- and SPECT-identified defects in dementia. *J Clin Psychiatry* 1994;55 (11, suppl):12-21.
33. Eberling JL, Jagust WJ, Reed BR, et al. Reduced temporal lobe blood flow in Alzheimer's disease. *Neurobiol Aging* 1992;13:483-91.
34. Friedland RP, Jagust WJ. Positron and single photon emission tomography in the differential diagnosis of dementia. In: Duara R, ed. Positron emission tomography in dementia: frontiers of clinical neuroscience series. Vol. 10. New York: Wiley-Liss, 1990:161-77.
35. Mayberg HS, Starkstein SE, Peyser CE, et al. Paralimbic frontal lobe hypometabolism in depression associated with Huntington's disease. *Neurology* 1992;42:1791-7.
36. Cummings JL. The neuroanatomy of depression. *J Clin Psychiatry* 1993;54 (11, suppl):14-20.
37. Baxter LR, Schwartz MJ, Bergman KS, et al. Caudate glucose metabolic rate changes with both drug and behavior therapy for obsessive-compulsive disorder. *Arch Gen Psychiatry* 1992;49:681-9.
38. Tamminga CA, Thaker GK, Buchanan R, et al. Limbic system abnormalities identified in schizophrenia using PET with fluorodeoxyglucose and neocortical alterations with deficit syndrome. *Arch Gen Psychiatry* 1992;49:522-30.
39. Liddle PF, Friston KJ, Frith CD, et al. Patterns of cerebral blood flow in schizophrenia. *Br J Psychiatry* 1992;160:179-86.
40. Deisenhammer E, Reisecker F, Leblhuber F, et al. Single photon emission computed tomography (SPECT) and X-ray CT in patients with dementia. *Psychiatry Res* 1989;29:443-5.
41. Komatani A, Yamaguchi K, Sugai Y, et al. Assessment of demented patients by dynamic SPECT of inhaled xenon-133. *J Nucl Med* 1988;29:1621-6.
42. Schwartz RB, Komaroff AL, Garada BM, et al. SPECT imaging of the brain: comparison of findings in patients with chronic fatigue syndrome, AIDS dementia complex, and major unipolar depression. *AJR Am J Roentgenol* 1994;162:943-51.
43. Rubbert A, Marienhagen J, Pimier K, et al. Single-photon emission computed tomography analysis of cerebral blood flow in the evaluation of central nervous system involvement in patients with systemic lupus erythematosus. *Arthritis Rheum* 1993;36:1253-62.
44. Rubbert A, Bock E, Schwab J, et al. Anticardiolipin antibodies in HIV infection: association with cerebral perfusion defects as detected by Tc-99m-HMPAO SPECT. *Clin Exp Immunol* 1994;98:361-8.
45. Tran Dinh YR, Mamo H, Cervoni J, Caulin C, Saimot AC. Disturbances in the cerebral perfusion of human immune deficiency virus-1 seropositive asymptomatic subjects: a quantitative tomography study of 18 cases. *J Nucl Med* 1990;31:1601-7.
46. Holman GL, Garada B, Johnson KA, et al. A comparison of brain perfusion SPECT in cocaine abuse and AIDS dementia complex. *J Nucl Med* 1992;33:1312-5.